

# WESTMEAD

## ‘Cardiac’

# QUESTIONS

# PRACTICE SAQ

## TIME = 66 mins

*Return Questions to Andrew Coggins –  
[andrewrcoggins@gmail.com](mailto:andrewrcoggins@gmail.com) or in  
Pigeon Hole at Westmead for marking  
and feedback*

# QUESTION 1

A 65-year-old man presents to the emergency department with a history of palpitations.

His vital signs are:

BP	105/60	mmHg
HR	156	beats/min
RR	26	/min
Temperature	36.2	°C

**His ECG is on the following page.**

- i. List the ECG abnormalities to support the diagnosis of Ventricular Tachycardia. (3 marks)

---

---

---

---

---

- ii. List four (4) clinical features that would influence your decision to urgently electrically cardiovert this patient. (4 marks)

1. 

---

2. 

---

3. 

---

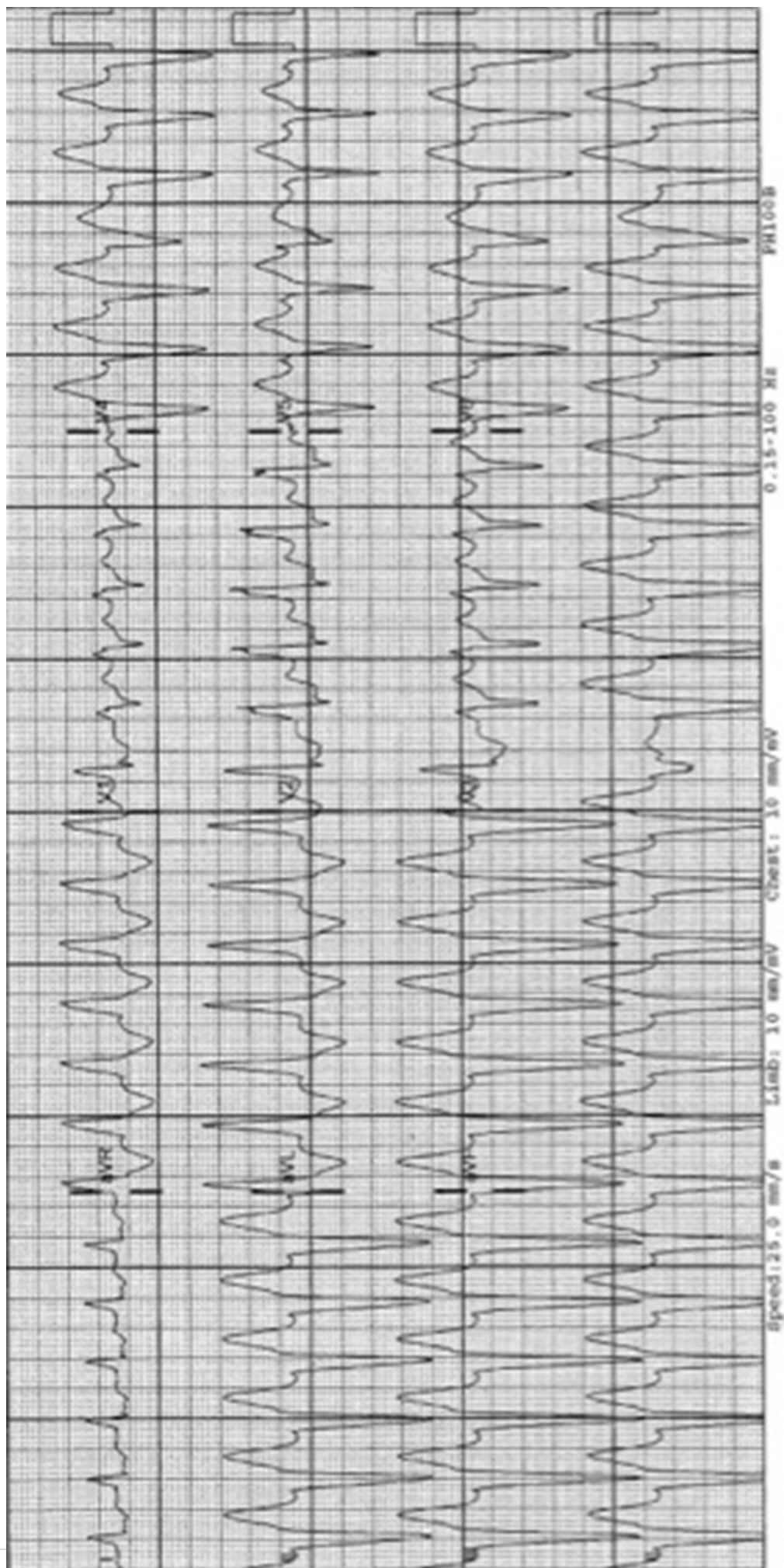
4. 

---

**(ECG on page 4)**

iii. Assuming none of these features are present, list three (3) choices for options for cardioversion, specifying intervention and doses. (3 marks)

	Intervention	Dossing
1		
2		
3		





## QUESTION 2

A 32 year old woman is brought to your emergency department from a shopping centre where she had a witnessed syncopal episode . On examination there is no evidence of trauma.

- i. List five (5) critical diagnoses you would consider and two (2) features (one (1) risk factor and one (1) symptom) that would support each of these diagnoses.

	Critical diagnosis	Risk Factor	Symptom
1			
2			
3			
4			
5			

ii. List and justify five (5) immediate investigations you would undertake.

	Immediate investigation	Justification
1		
2		
3		
4		
5		

## QUESTION 3

A 67-year-old lady presents to the Emergency Department (ED) with a history of increasing Shortness of Breath over the last 2 days. She is brought in by ambulance and was given an anti-emetic on route. She has a past medical history of Diabetes Mellitus, Lung Cancer (NSCLC) and Hypertension

- Observations:

Blood Pressure 89/60 Respiratory Rate 20/min

Heart Rate 115 Temperature 37.4 degrees

Oxygen Saturations 100% (on 6 litres by Hudson Mask)

i) Describe the patient's Electrocardiogram. (5 marks)

---

---

---

---

---

---

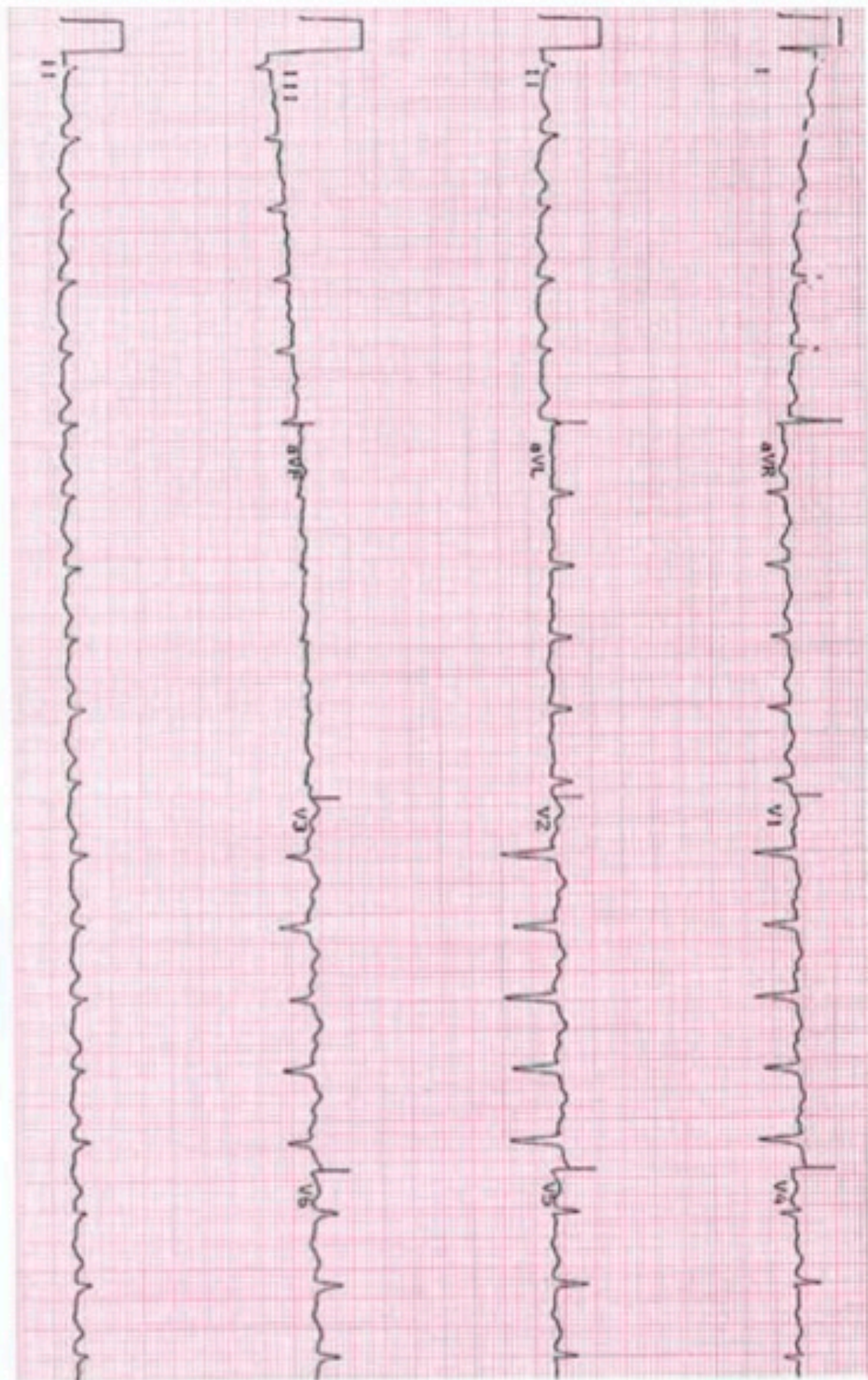
---

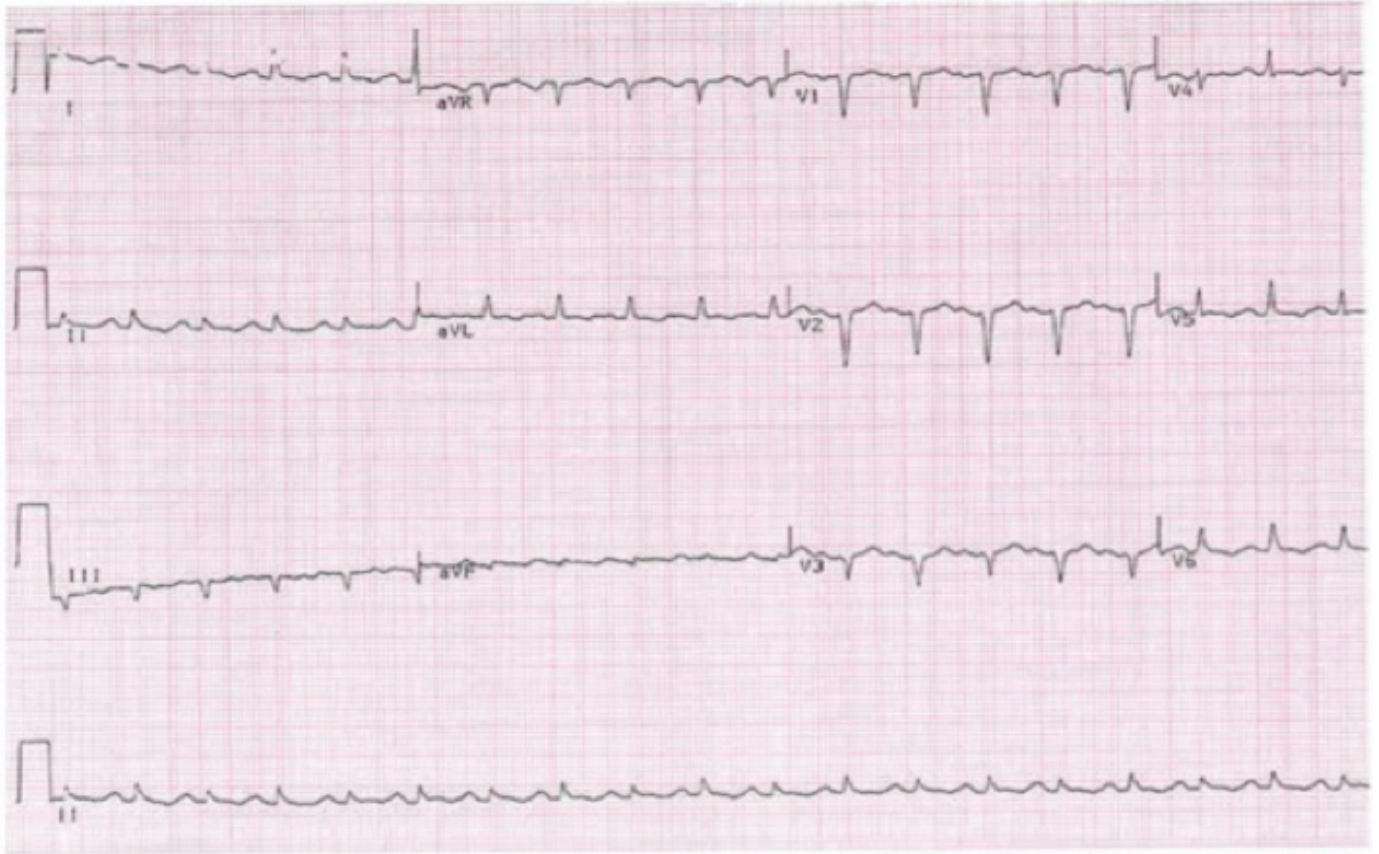
---

---

---







ii) List 5 differential diagnoses in this patient (5 marks)

---

---

---

---

---

---

## QUESTION 4

A 66-year-old man with heavy smoking history and a diagnosis of COPD presents with shortness of breath and palpitations. He has had an increasing cough and sore throat over the last 2 days.

Medications include Tiotropium, Seretide and Salbutamol. The patient is not on home oxygen.

- Observations:

Blood Pressure 110/70 Respiratory Rate 25/min

Heart Rate 120 (irregular) Temperature 37.7 degrees

Oxygen Saturations 91% (on Room Air)

—

I) Describe this patient's 12 lead ECG (5 marks)

---

---

---

---

---

---

---

---

---

---

---

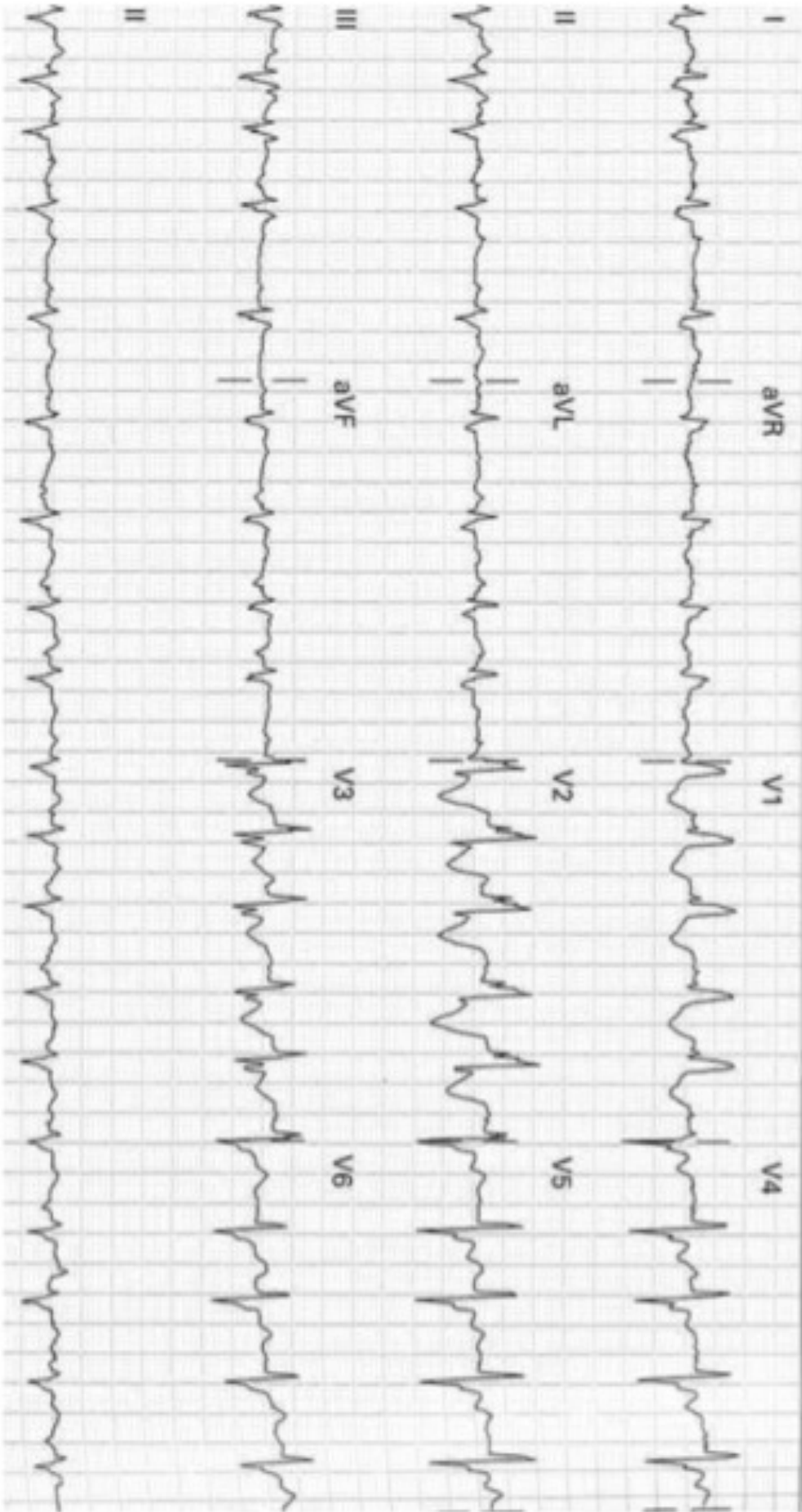
---

---

---

---

---



II) List 5 differential diagnose for this patient's presentation and ECG (5 marks)

---

---

---

---

---

---

## QUESTION 5

You are the only consultant working a busy evening shift in emergency department when the triage nurse tells you that 19 patients have self-presented to triage in the last five minutes with having ingested a large quantity of “oleander tea” as part of a game at a music festival. An ambulance has turned up with a sixteenth patient from the festival complaining of palpitations.

i. What further information do you ask the ambulance officer? (3 marks)

---

---

---

---

---

---

---

---

---

---

II) What key steps do you take to:

a. Prepare your emergency department for this situation? (4 marks)

---

---

---

---

---

---

---

b) Prepare the hospital for this situation? (3 marks)



## QUESTION 6

It is 2030 hours on a weeknight. You are the duty doctor in a tertiary level emergency department.

The department currently has all cubicles occupied except for two which are unmonitored.

Ambulance control rings to notify you that an ambulance is en route to your department with a 54 year old man with a probable acute myocardial infarct. Estimated time of arrival is 5 minutes.

All five of your resuscitation cubicles are occupied by the following patients:

- 1) A 75 year old lady with unstable angina. She is awaiting a bed in the cardiology unit.
- 2) A 50 year old man with resolved chest pain and normal ECG. He has just arrived by ambulance and is yet to be assessed.
- 3) A 3 year old girl with croup. She is now stable 30 minutes after nebulised adrenaline.
- 4) A 22 year old man being monitored 2 hours following an overdose of the drug Carbamazepine.
- 5) A 17 year old man with a closed head injury. He is about to be intubated by your registrar because his GCS has fallen to 9/15.

I) How will you prepare to accommodate this patient ? (3 marks)

---

---

---

---

---

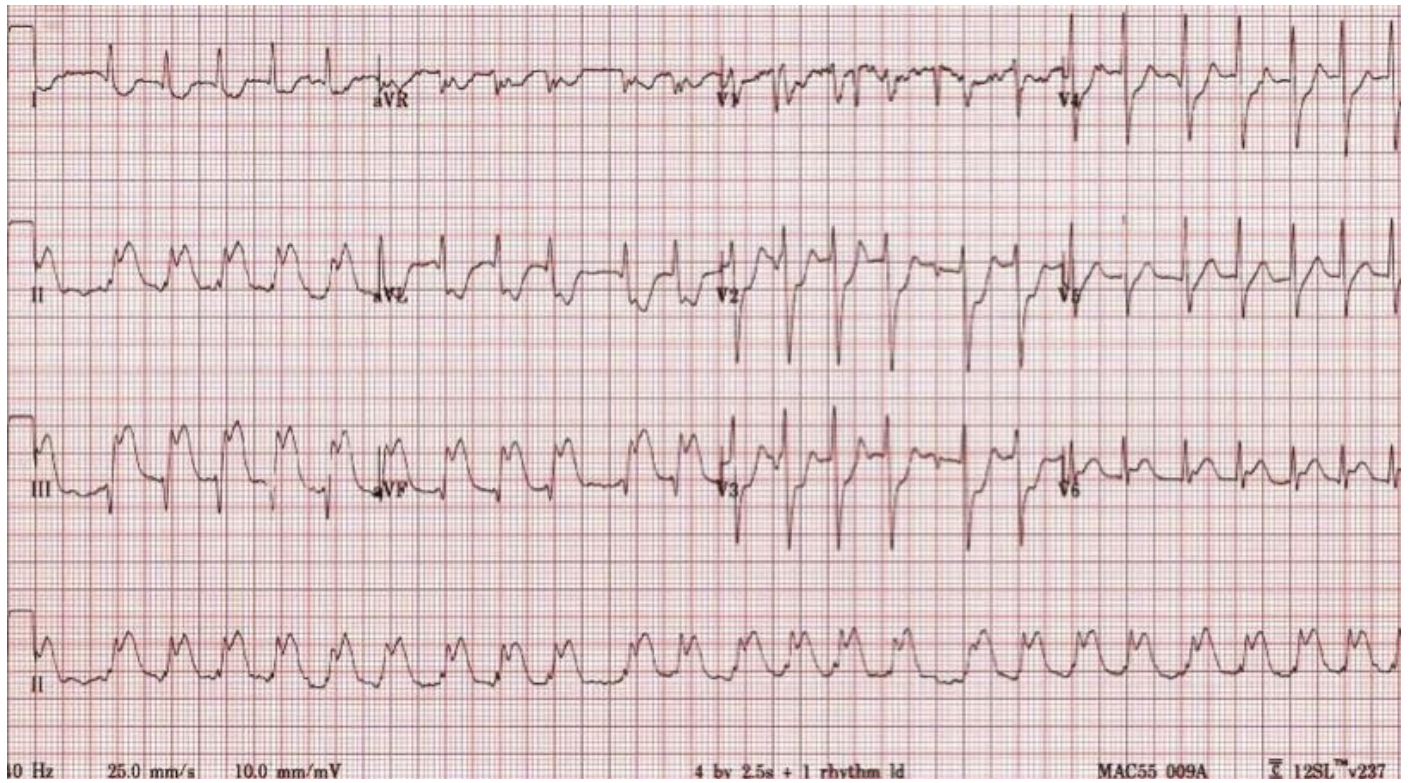
---

---

---

II) The patient arrives please comment on his ECG (3 marks)





- III) The patient has a short run of non-sustained VT. Describe 3 antiarrhythmic agents that could be use specifying drug, dose as well as 1 pro and 1 con

Drug	Dose	Pro	Con
1			
2			
3			
4			

## QUESTION 7

A 32 year old female is brought to your ED by ambulance with a suspected drug overdose.

Her ECG on arrival is shown on the next page.

Her observations are as follows

BP90/60

HR 140

Sats 94% on Non rebreather mask

Resp Rate 10

GCS 14/15

I) Describe the abnormalities on the ECG and state the most likely cause (4 marks)

---

---

---

---

---

---

---

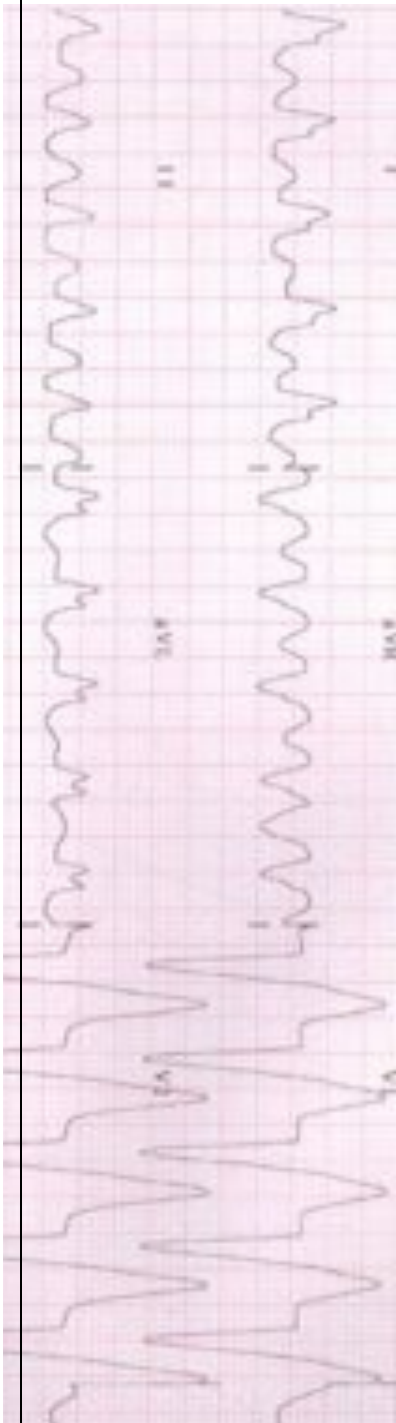
---

---

MOST LIKELY CAUSE =

---

---



II) The patient's partner reveals she has taken >40 of her prescribed antidepressant tablet.

Outline the key steps in the initial management plan for this patient in the ED (6 marks)

[illegible]

## QUESTION 8

A 6 month old child is found by his parents to be cyanosed and unresponsive in bed. He is brought to the Emergency Department where he dies despite extensive resuscitative efforts. The parents are anxiously awaiting the outcome.

a) List your how you would estimate the following factors for a Paediatric patient suffering a Cardiac Arrest in the ED

i. Weight

1 mark

---

ii. Defibrillation Joules

1 mark

---

iii. Endotracheal Tube Size(s)

1 mark

---

iv. Fluid Bolus

1 mark

---

v. Glucose Bolus for Hypoglycaemia

1 mark

---

vi. Adrenaline dosing for cardiac arrest

1 mark

This image shows a blank sheet of white paper with horizontal ruling lines. The lines are evenly spaced and run across the width of the page. There are no margins, text, or other markings on the paper.

## QUESTION 9

A 48-year-old man presents to the Emergency Department (ED) with a history of Cardiac Arrest at the local supermarket.

CPR was started by bystanders immediately.

He received 2 DC Shocks by the ambulance paramedics and has a Return of Spontaneous Circulation (ROSC) prior to arrival in the ED

- Triage – ATS Category 2
- GCS 6

- Observations:

Blood Pressure 80/50                      Respiratory Rate                      15/min (spontaneous)

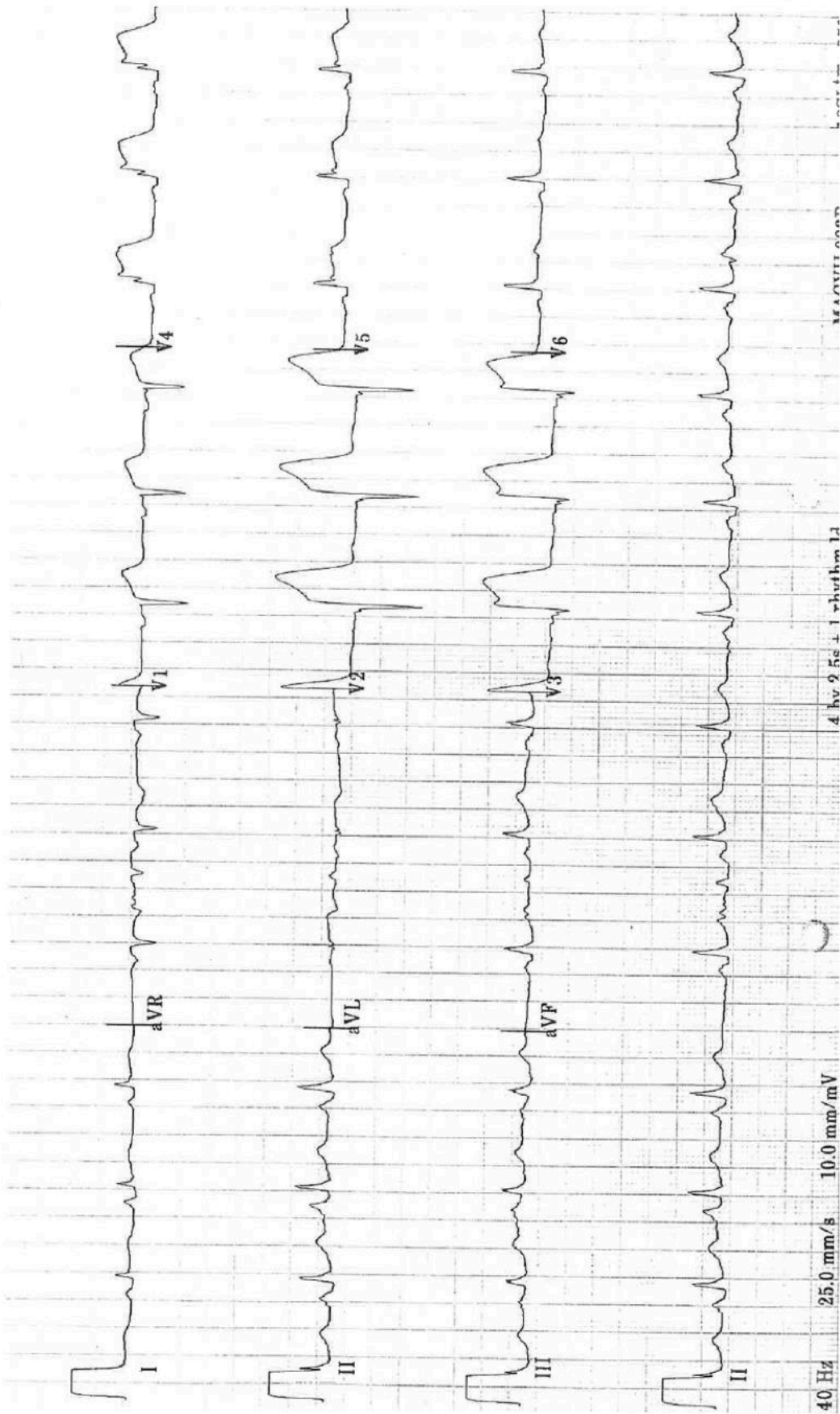
Heart Rate 75                                  Temperature                      36.1 degrees

Oxygen Saturations 99%                      (on 10 litres by Hudson Mask)

- a) List the abnormalities on this patient's Electrocardiogram.                      3 marks
- b) List 6 differentials for ST elevation on an ECG                      3 marks
- c) Outline your management priorities after a ROSC in the ED                      4 marks

*(ECG on next page)*





I) Describe the abnormalities on this patient's Electrocardiogram. 3 marks

---

---

---

---

---

---

---

---

---

---

II) List 6 differentials for ST elevation on an ECG 3 marks

---

---

---

---

---

---

---

---

---

---

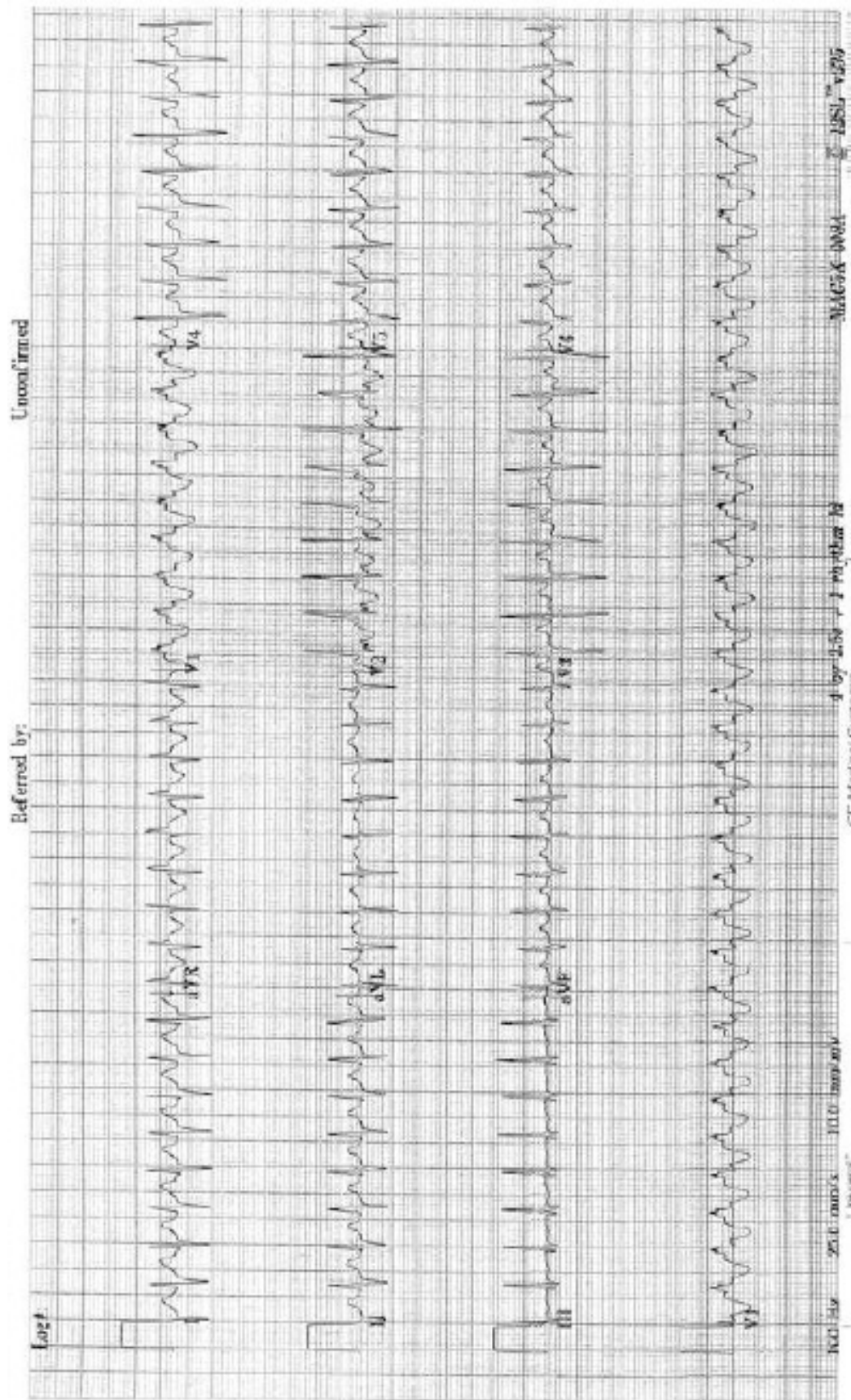
III) Outline your management priorities after ROSC in the ED 4 marks

[illegible]

## QUESTION 10

**A 3 month old infant presents with irritability and poor feeding.**

**- His ECG is shown below:**



I) List the abnormalities on the ECG and give 4 differentials

5 marks

This image shows a blank sheet of white paper with horizontal ruling lines. The lines are evenly spaced and run across the width of the page. There are no margins, text, or other markings on the paper.

II) Outline your initial management in the ED

4 marks

[illegible]

---

---

---

---

---

## QUESTION 11

A 64 year old man is being evaluated in your emergency department after an episode of chest pain which has now resolved.

His observations are:

BP 140/85 mmHg supine

HR 30

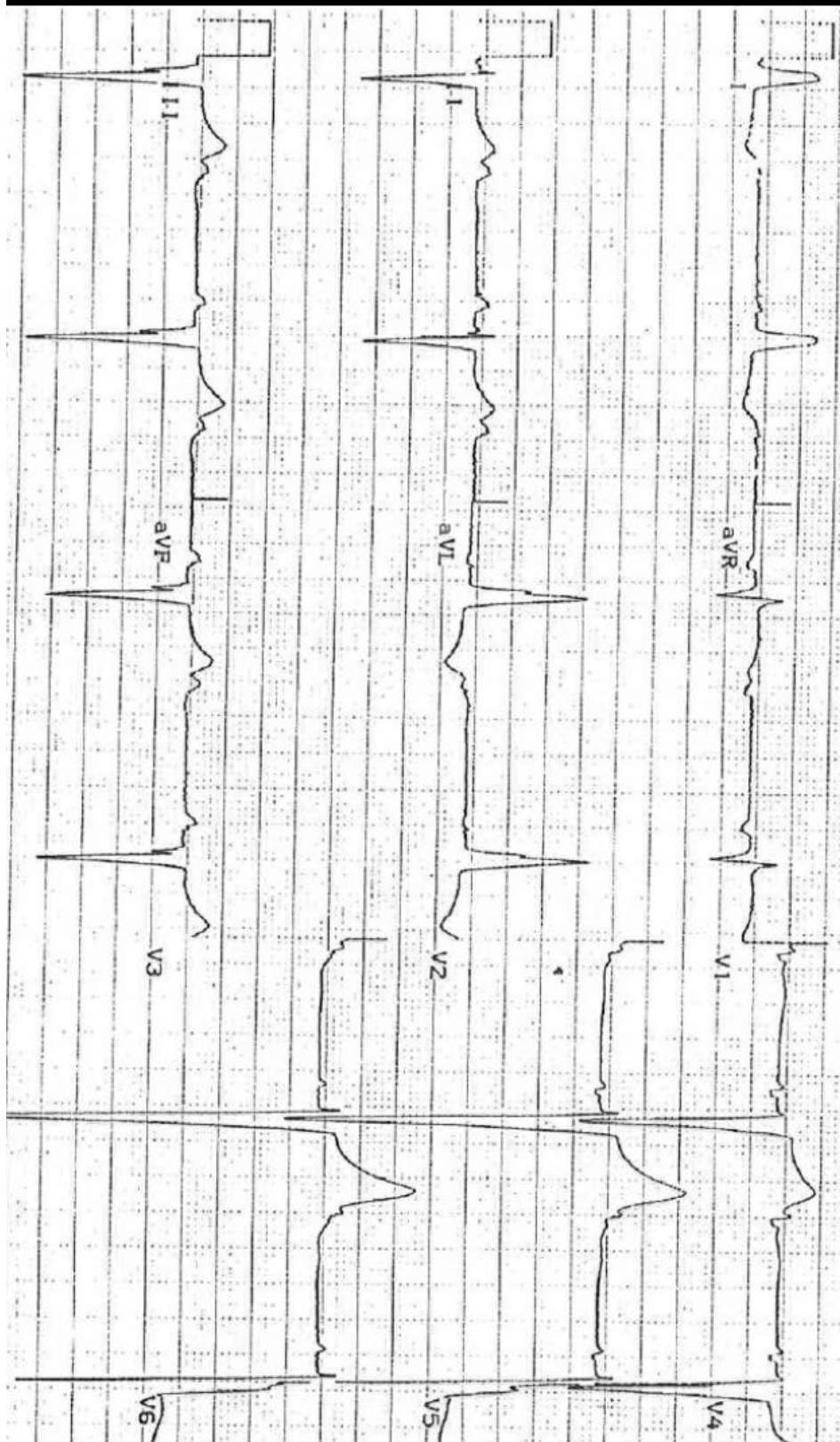
RR 20 /min

O2 saturation 97% room air

ECG shown on next page

Describe and his ECG and List 4 potential causes of this rhythm abnormality (6 marks)

This image shows a blank sheet of white paper with horizontal ruling lines. The lines are evenly spaced and run across the width of the page. There are no margins, text, or other markings on the paper.





[illegible]